



# Evaluation of implant stability simultaneously placed with sinus lift augmented with putty versus powder form of demineralized bone matrix in atrophied posterior maxilla

Lobna Abdel Aziz Aly <sup>a,\*</sup>, Nelly I Hammouda <sup>b</sup>

<sup>a</sup> Faculty of Dentistry, Future University, Cairo, Egypt

<sup>b</sup> Faculty of Dentistry, Mansoura University, Cairo, Egypt

## ARTICLE INFO

### Article history:

Received 28 November 2016

Received in revised form

21 December 2016

Accepted 22 December 2016

Available online xxx

### Keywords:

Implant stability

Sinus lift

Putty and powder DBM

## ABSTRACT

**Background:** Rehabilitation of edentulous posterior maxilla with dental implants is a challenging problem in oral and maxillofacial surgery due to alveolar resorption and excessive pneumatization of maxillary sinus. This study was designed to compare the efficacy of Putty Versus Powder Form of Demineralized Bone Matrix (DBM) augmented in lifted maxillary sinus in atrophied posterior maxilla with evaluating the implant stability simultaneously placed with both of them.

**Patients and Methods:** sixty four implants were placed in twelve patients in the period between 2013 and 2016. Lateral approach, open window method for sinus lift with peizosurgical unit and placement of Putty or Powder Form of DBM were carried out simultaneously with implant placement. The implant success was defined when the prosthesis had been delivered and followed for 18 months without infection, pain, marginal bone loss and the implant stability quotient (ISQ) of each implant was measured using resonance frequency analysis.

**Results:** Radiographic bone formation was evident in all 12 patients, and all implants were stable after 18 months of placement. No statistically significant differences were observed in marginal bone loss around the implants between the powder and the putty groups at 6 months ( $p = 0.60$ ), 12 months ( $p = 0.85$ ) and 18 months ( $0.49$ ). The difference between ISQ values in both groups was only significant at the baseline ( $p = 0.023$ ).

**Conclusion:** Sinus lifting with simultaneous implant placement could be used to treat atrophic maxilla with initial stability obtained by using taper designed implants and with minimal intraoperative complication using peizosurgery. No statistically significant differences in the stability were observed between implants placed with both putty and powder forms of DBM.

© 2016 Faculty of Oral & Dental Medicine, Future University. Production and hosting by Elsevier B.V. This is an open access article under the CC BY-NC-ND license (<http://creativecommons.org/licenses/by-nc-nd/4.0/>).

## 1. Introduction

Recently, clinicians have recommended augmenting the maxillary sinus to facilitate placement of endosseous implants in the severely atrophic posterior maxilla [1]. There are various techniques for sinus lift such as lateral window, crestal approach,

summers osteotomy, bone aided augmentation. The most popular technique for sinus lift is found to be lateral window with autogenous corticocancellous grafts. The most effective standardized grafting material is autogenous bone grafts due to osteoinductive and osteoconductive potential [2–4]. Various alternative materials have also been used however compromising the osteoinductive potential, such as allografts, xenografts and alloplastic grafts that used for bone substitution to make implantation more predictable and successful clinically [4–7].

Over the years demineralized bone matrix (DBM) has been frequently used for bone grafting. DBM contains active proteins such as bone morphogenetic protein (BMP), transforming growth factor-beta (TGF- $\beta$ ), osteogenin, insulin-like growth factor, and

\* Corresponding author. 90th street New Cairo, Cairo, Egypt. Tel.: +20 1001324032.

E-mail addresses: [Lobna72@gmail.com](mailto:Lobna72@gmail.com) (L.A.A. Aly), [Nonalytaj1@yahoo.com](mailto:Nonalytaj1@yahoo.com) (N.I. Hammouda).

Peer review under responsibility of Faculty of Oral & Dental Medicine, Future University.

<http://dx.doi.org/10.1016/j.fdj.2016.12.001>

2314-7180/© 2016 Faculty of Oral & Dental Medicine, Future University. Production and hosting by Elsevier B.V. This is an open access article under the CC BY-NC-ND license (<http://creativecommons.org/licenses/by-nc-nd/4.0/>).

fibroblast growth factor, which are mostly regarded as members of the TGF- $\beta$  superfamily [8]. In recent years, several studies have demonstrated the success of DBM for reconstructive maxillofacial surgery, and sinus augmentation is used in various graft sizes and forms [9–11].

The types of DBM based on particulate size, survival of implants and operation time have been compared, resulting in no significant difference in terms of implant success during the loading time, but the putty form was found to be more successful than the powder form for the ease of application and operation time. Also, optimal bone induction was found with DBM particle sizes of 250–500  $\mu\text{m}$ . On the other hand, marginal bone resorption and implant success between the putty and powder forms has not been evaluated [10,12].

Implant stability can be defined as the absence of clinical mobility, which considered to be the most important prerequisite for success of osseointegrated dental implants. Implant success is influenced by primary stability factors such as implant diameter, shape, thread forms and pitch values, and adequate bone height. While the secondary stability factors included the host environment where bone density plays a vital role in their placement and successful osseointegration [13].

Primary stability can be measured by different methods [14]: “biomechanical tests, including insertion and disinsertion torque measurements, and non-invasive techniques such as resonance frequency analysis (RFA)”. RFA offers a clinical measure for implant stability and presumed osseointegration and make it possible to measure implant stability without damaging the bone-implant junction [15]. Most studies have focused on implant stability in augmented posterior regions of maxilla after osseointegration [15,16].

The aim of this study was to compare the dental implant stability and the marginal bone resorption around dental implants placed simultaneously placed with sinus lifting using peizosurgery and the efficacy of augmentation with putty and powder forms of DBM.

## 2. Patients and methods

Twelve patients referred to private practice in Cairo, Egypt, for bilateral maxillary sinus lifting between 2013 and 2016. The study was conducted in accordance with the moral, ethical, regulatory, and scientific principles governing clinical research as set out in the Declaration of Helsinki (2013). All patients were fully informed about the treatment prior to the surgical procedure and provided written consent for the procedure. All procedures and materials were approved by the local Ethics Committee of Future University, Egypt.

A preoperative computer tomography scan was used to quantify the amount of available bone at individual implant sites under the maxillary sinus to decide whether the patient could be included in the study. Before the procedure, the anatomy and pathology of the sinuses were evaluated using panoramic view (Fig. 1). The width of the alveolar bone ridges was considered a noninterfering parameter because the width was always sufficient for a secure implantation. According to Cawood-Hawell's classification [17], Class V and VI cases were included in the study. Patients who had residual bone height less than 2 mm were excluded. The other exclusion criteria were sinus pathologies, systemic diseases, smoking habits, alcohol consumption and poor oral hygiene. All patients underwent bilateral.

sinus surgery and the residual bone height of the edentulous sites for implant placement was measured, a 4–6 mm of the bone level was required in the alveolar ridge for primary stability, with sufficient inter-arch space for the prosthesis.

Treated lateral window open sinus lifts performed bilaterally on 12 partially or completely edentate patients (8 males and 4 females, aged 49–68 years) with a piezoelectric surgery unit. Patients were treated under local anesthesia using articaine 4% with 1:100,000 epinephrine. After elevation of a full-thickness flap, all cases had their lateral antrostomies created by outlining an island of bone or completely removing the entire lateral aspect of the window using the piezoelectric unit according to the manufacturer's instructions. The elevation of the Schneiderian membrane was accomplished by initially exposing and mobilizing the membrane using the piezoelectric hand piece followed by hand instrumentation to further elevate the membrane along the medial wall of the sinus (Fig. 1).

A total of 24 sinus lifts were performed and 64 tapered dental implants (Implant Microdent System S.L-Comapedrosa, Barcelona, Spain) measuring 3.4–5.0 mm in width and 12–14 mm in length were placed concurrently with sinus augmentation to achieve primary stability. In all patients, the left side was grafted with DBM putty form (DynaGraft Keystone Dental, Burlington, Massachusetts) and the right side was grafted with DBM powder form (Pacific Coast Tissue Bank, Los Angeles, California) after a minimum of 30 min rehydration process in 0.9% Saline solution. The lateral wall of the sinus was then covered with a membrane (Bio-Gide, Geistlich Pharma AG) (Fig. 2).

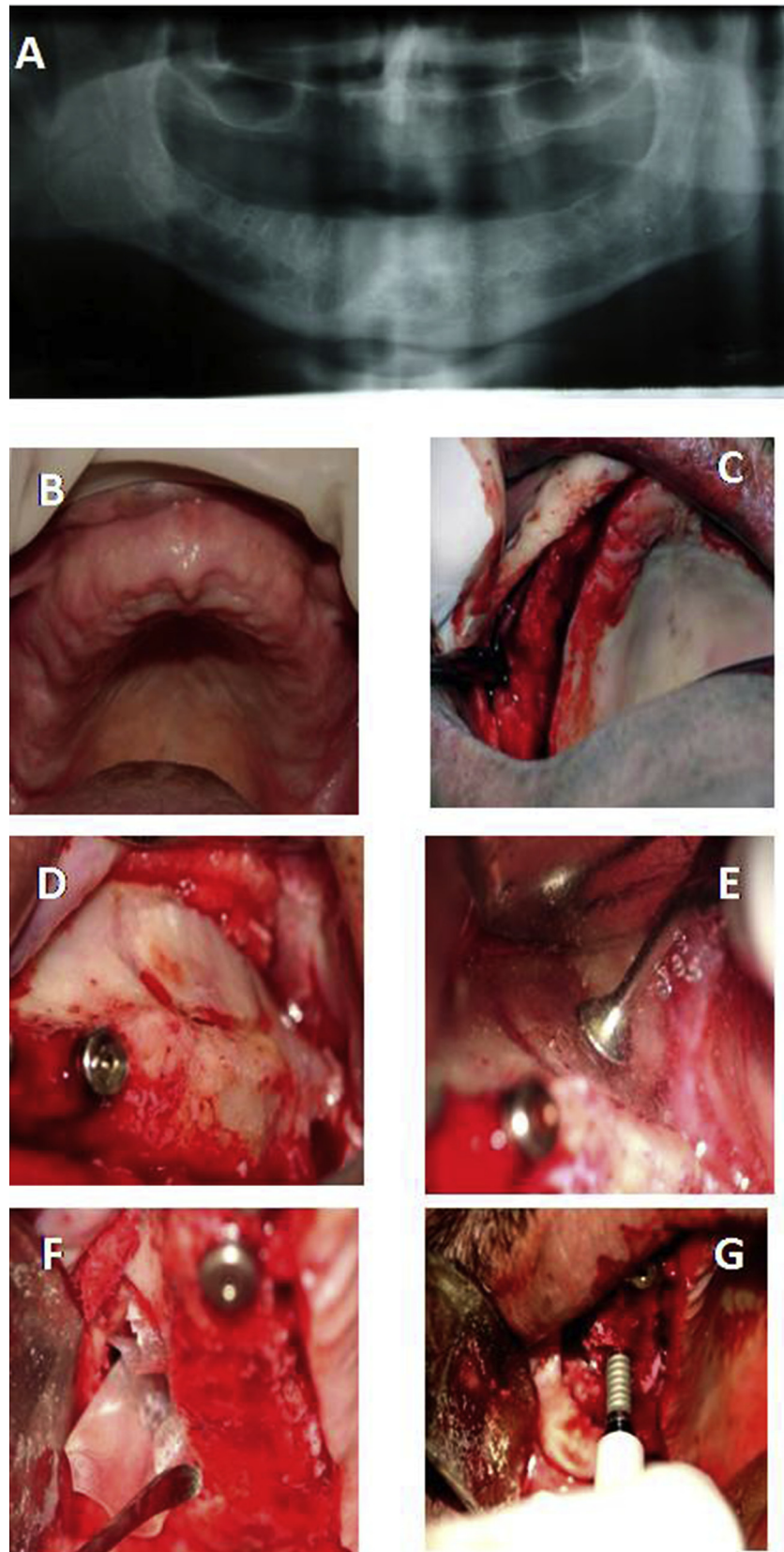
After the graft had been placed, the flap was re-positioned and sutured with 3/0 silk suture. Antibiotic (Augmentin 625 mg, Glaxo Smith Kline, Egypt) and analgesic (BRUFEN 600 (Ibuprofen 600 mg)) therapy was administered 1 h before surgery and for 5 days following the surgery. Chlorohexidine gluconate 0.12% mouthwash was used twice daily for 2 weeks. The patients were advised to have a soft diet and to avoid sneezing till suture removal.

None of the implants were loaded before a minimum of 6 months from the date of first surgery. Implants were manually tested for stability when unscrewing the cover screws and impressions were taken with pick-up impression copings using a polyether material (Impregum 3M/ESPE, Neuss, Germany) with customised resin impression trays. The vertical dimension as registered and models were made with class 4 precision plaster and mounted in standard articulators. Implant stability as manually checked by tightening the abutment screws with a 20 Ncm torque, and definitive restorations were delivered.

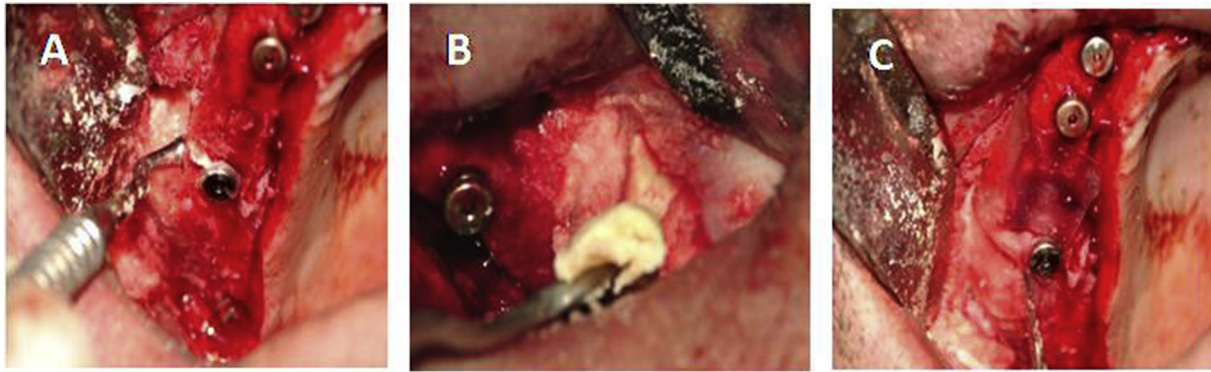
### 2.1. Clinical and radiographic evaluation

One dentist not involved in the treatment of the patients, made all clinical assessments without knowing group allocation, therefore outcome assessor was blind. Implant success was evaluated based on the clinical and radiologic criteria [18,19] that included: absence of mobility; absence of persistent subjective complaints (pain, foreign body sensation and/or dysaesthesia); absence of a continuous radiolucency around the implant; and marginal bone level changes in the first year implant insertion less than 1–1.5 mm and the ongoing annual bone loss less than 0.2 mm. Marginal bone loss around mesial and distal side of the implants were measured (in mm) at implant placement, at the time of loading, after 12 and 18 months of placement. For measurements purposes, 2 visible and easily localized reference points were selected at the junction point between the implant and prosthetic restoration. A straight line was traced joining the 2 reference points. The marginal bone resorption was determined by measuring between this line and the highest crestal bone point around the implant.

The implant stability quotient (ISQ) of each implant was measured using resonance frequency analysis (an Osstell device (Integration Diagnostic AB, Svedalen, Sweden)) on the day of surgery (baseline, ISQ0) and monitored at 14 days (ISQ1), 30 days (ISQ2) and 60 days (ISQ3) post-implantation in each group.



**Fig. 1.** A) An OPG view of a patient with deficient vertical bone height. B) Preoperative clinical picture of completely edentulous alveolar ridge. C) Elevation of a full-thickness flap that was initiated slightly palatal to the crest of the ridge. D) Bony cut was done to outline the window to be opened on the lateral wall of the maxillary sinus. E) Partially raised lining was then lifted to a greater extent using the BS4 & BS5 tips. F) The bony window was pushed and rotated horizontally along with membrane elevation and a Bio-Gide membrane is inserted under the elevated sinus membrane. G) Implant was placed in the pre-prepared bed.



**Fig. 2.** A) Powder form of DBM filled the space created by sinus lift procedure in the right side. B) Putty form of DBM filled the space created by sinus lift procedure in the left side. C) The grafted material were condensed and covered with a Bio-Guide membrane in both groups.

## 2.2. Statistical evaluation

Statistical analyses were performed with SPSS 11.5. Two way repeated measures analysis of variance (ANOVA) and Fisher's LSD tests were used for between and within group comparisons in different time points. A *p* value less than 0.05 were considered significant.

## 3. Results

Of the 12 patients, 8 (66.6%) were males and 4 (33.3%) were females. The overall age range of the patients was 49–68 years. All implants with upper prosthesis had a 100% survival rate at the point of final observation. All implants osteointegrated successfully in both grafted sides and showed successful results. Six months after surgery, all implants were clinically stable during abutment tightening. Patients' and interventions' characteristics are summarized in (Table 1).

Radiographic bone formation was evident in all 12 patients, and all implants were stable after 18 months of placement. The newly formed sinus floor was smooth, showing that there was no perforated area. No change of membrane thickness was seen. The graft area was clearly visible in the radiograph and could be distinguished from the existing alveolar bone. The average alveolar ridge height was  $15.6 \pm 2.5$  mm 6 months postoperatively.

### 3.1. Peri-implant marginal bone level changes

Means bone levels up to 18 months post-placement are presented in Table 2. There was no statistically significant difference between the 2 groups for peri-implant bone level changes at loading ( $P = 0.83$ ) and 18 months after placement ( $P = 0.56$ ) (Table 3). Both groups gradually lost marginal peri-implant bone at loading ( $P < 0.0001$ ) and at 18 months after placement ( $P < 0.001$ ) (Table 3). 18 months after placement, patients of the putty group

lost an average of 1.01 mm peri-implant bone versus 0.93 mm of the powder group (Table 3).

The mean ISQ value in both groups is shown in (Fig. 3). The difference between ISQ values in both groups was only significant at the baseline ( $p = 0.023$ ). The correlations between the ISQ0, ISQ1, ISQ2 and ISQ3 values in each group were evaluated. In the putty DBM group, correlations between ISQ values were significant between ISQ0 and ISQ1 ( $r = 0.690$ ,  $p = 0.006$ ), ISQ1 and ISQ3 ( $r = 0.569$ ,  $p = 0.034$ ) and ISQ2 and ISQ3 ( $r = 0.540$ ,  $p = 0.046$ ). In the powder DBM group, the correlation was significant only between ISQ0 and ISQ1 ( $r = 0.716$ ,  $p = 0.002$ ).

## 4. Discussion

The sinus lift procedure with bone augmentation is now a well accepted technique for rehabilitation of the posterior atrophic maxilla with implant placement. Simplicity, less invasive, complication-free technique is the most important rules in the success of grafting procedure [20].

Shrinkage and ossification of the blood clot around titanium implants placed in the maxillary sinus and the formation of a new sinus floor have been observed in several studies. Nonetheless, irrespective of the bone-forming site, bone formation and healing require the recruitment, migration and differentiation of osteogenic cells. The lifting of the periosteum may have initiated a resorption process, exposure of the bone marrow and access of stem cells to the sinus cavity, a sequence of events that has been described in animal studies [21,22].

The lateral window sinus lift is the traditional treatment option of choice prior to implant placement when  $<5$  mm of residual bone remains between the alveolar crest and the maxillary sinus [23,24]. This approach using a "window" in the lateral bony wall of the maxillary sinus to gain access to the underlying Schneiderian membrane [25]. Although implant survival rates associated with this procedure routinely exceed 90% [26,27], the lateral window

**Table 1**  
Patients' and interventions' characteristics.

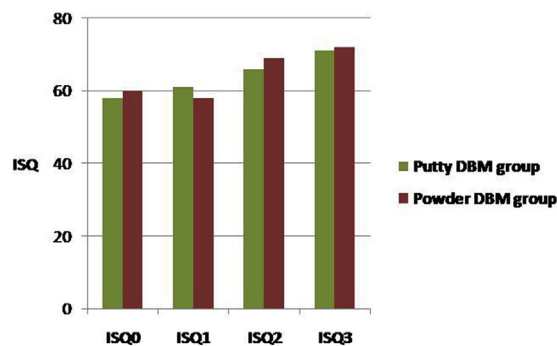
	Putty DBM group	Powder DBM group
Number of lifted sinuses	12	12
Age at insertion (range)	49–68 years	49–68 years
Total number of implants placed	36	28
Implants inserted with a torque up to 30 Ncm	23	4
Implant inserted with a torque $>30$ Ncm	13	24
Sites characterised by soft bone quality	23	6
Sites characterised by medium bone quality	13	22
Sites characterised by hard bone quality	0	0

**Table 2**  
Mean radiographic peri-implant marginal bone levels at different time periods and between groups.

	Implant placement Mean (SD)	Loading Mean (SD)	18 month after placement Mean (SD)
Putty DBM group (n = 36)	0.47 (0.36)	1.14 (0.65)	1.51 (0.63)
Powder DBM group (n = 28)	0.24 (0.24)	0.86 (0.39)	1.17 (0.45)
Difference	0.23	0.27	0.32
P value	0.004	0.065	0.033

**Table 3**  
Mean radiographic peri-implant marginal bone level changes between time periods and groups.

	Implant placement- loading		Implant placement – 18 month after placement	
	Mean (SD)	P value	Mean (SD)	P value
Putty DBM group (n = 36)	-0.64 (0.54)	<0.001	-1.01 (0.56)	<0.001
Powder DBM group (n = 28)	-0.61 (0.34)	<0.001	-0.93 (0.40)	<0.001
Difference	-0.026		-0.08	
P value	0.83		0.56	



**Fig. 3.** The implant stability quotient (ISQ) of each implant was measured along the follow up period.

sinus lift remains a technique-sensitive procedure due to the high risk of Schneiderian membrane perforation and hemorrhagic complications which is associated with the inadvertent laceration of the intraosseous arterial supply to this region [28,29].

In order to overcome these drawbacks, peizosurgical technique was used in the current study, as this technique prevents perforation which was proved by histological studies which reveal that this procedure increases the concentration of bone morphogenic protein (BMP-4), Transforming Growth Factor (TGF) beta-2, Tumor Necrosis Factor [30,31]. The piezoelectric device has the ability to automatically cease surgical action when comes into contact with non mineralized tissue. Thus peizosurgical technique was comparatively a safe approach to the maxillary sinus, allowing the sinus membrane integrity to be maintained during surgical procedures when compared to conventional techniques [32].

DBM powder is the most osteoinductive form as it possesses the maximum surface area for interaction with target cells at the graft site [11]. However, there were clinical problems associated with the use of powdered and particulated forms such as difficulties with handling, its tendency to migrate from the graft sites, and lack of stability after surgery [10,11,33]. Various carrier materials had been developed facilitating the handling of DBM powder such as glycerol, fibrin sealant, hyaluronic acid, lecithin, polyorthoester, polyethyleneoxide-polybutylene terephthalate (PEO-PBT) copolymer, polylactic-co-glycolic acid (PLGA) and Poloxamer 407 [11].

The present study compared the implant stability and marginal bone levels of dental implants immediately placed into grafted maxillary sinus with powder and putty forms of DBM. There have been studies comparing the types of DBM based on particulate size, survival of implants and operation time [8,10]. In these studies, there were no significant difference in terms of implant success during the loading time, but on the other hand the putty form was found to be more successful than the powder form for the ease of application and operation time. In the present study, DynaGraft was used in one side of the patients as a putty form and the other side as powder form for sinus graft material. DynaGraft is a unique graft substitute composed of a high content of human DBM, and is designed to promote natural bone formation [10]. The findings of this study, were no significant differences between both putty and powder DBM groups after 18 months from placement as regard marginal bone levels of dental implants.

The average residual bone in this study was 4–6 mm and the simultaneous grafting was performed. As Fugazzotto [34] reported that when greater than 4 mm of bone remains coronal to the sinus, a sinus grafting with implant placement could be performed simultaneously. The one-step procedure offers the advantages of reducing the number of surgical procedures and the time needed. Tarnow et al. [35] reported that the implant with membrane showed a higher survival rate and more vital bone than the implant without a membrane. The membrane in this study was used to give more stability to the graft and to prevent the migration of the graft particles. It is well known that bone can be formed in secluded spaces on a bone surface by using various types of barrier membranes or other space-making devices.

Delayed implant placement resulted in a mean marginal bone loss three times greater than that of simultaneous implant positioning [36,37]. Primary implant stability and graft is related to adequate bone height. Delayed implant placement is not recommended for badly destructed alveolar ridge with no proper implant base [38]. In the current study, all implants were performed with simultaneous sinus lifting and demonstrated acceptable results in line with these studies as regard the mean marginal bone loss. A systematic review about simultaneous sinus lifting and implant placement reported a survival rate of 90.1% after 3 years of follow-up [39]. The benefits for sinus lifting and simultaneous implant placement are the following: reduced number of surgeries, reduced treatment time, and lateral window access to the maxillary sinus during implant placement.

Obviously, one major goal in implant dentistry is to avoid implant failure. Although the failure rate of implants used in two-stage procedures is rather low, it is likely that higher failure rates are associated with immediate loaded or grafted implants. Because primary stability is important in achieving osseointegration [36], selecting implants that maximize primary stability is essential when bone is limited in the maxillary sinus. Fixture designs (e.g., implant taper) can affect the initial stability of the implant [40]. In this study, tapered implants were used and had high success rates as they increase the compression of bone and primary stability when placed into a conventional parallel osteotomy [41].

Degidi et al., in 2009 evaluated the ISQ values at 6 and 12

months from the implant insertion in sinus grafted and non-grafted sites. Sites treated with open sinus lift could offer good long-term stability. After 6 and 12 months, the geometric characteristics of the implant were no longer important to obtain high RFA values, and the bone implant contact was determinant [16], thus in the present study, implant stability was measured at four intervals for each implant; namely, immediately after placement as the primary stability, day 14 as the time for the newly formed woven bone around the implant, day 30 as the time when the woven bone lines most parts of the implant surface and the start of the remodeling phase, and finally day 60 as the time at which the implant surface is lined with lamellar bone as accepted in the literature for loading [42,43]. There was significant difference between ISQ values in both groups in the current study at the baseline, the difference had disappeared after the first month, and this could be explained by the occurrence of osseointegration.

## 5. Conclusions

In conclusion, a lateral approach to sinus elevation using piezosurgery technique was an effective mean to achieve sinus elevation with minimal intraoperative complications. Both putty and powder forms of DBM showed no significant difference as regard implant stability and also had no significant difference at marginal bone loss around dental implants and survival rates according to long-term follow up. DBM is considered as a good alternative graft material for augmentation of lifted sinus simultaneously with implant placement in atrophied posterior maxilla.

## Disclosure

There was no financial assistance from any source for this study.

## Contribution of author

Aly L: Concept/Design, surgical procedure, Data collection, Data analysis/interpretation, writing article, Critical revision of article.

Hammouda N: Surgical procedure, data collection, Data analysis/interpretation.

## Conflict of interest

The authors have stated explicitly that there are no conflicts of interest in connection with this article.

## References

- [1] Hochwald DA, Davis WH. Bone grafting in the maxillary sinus floor. In: Worthington P, Brånemark P-I, editors. *Advanced osseointegration surgery: application in maxillofacial region*. Chicago: Quintessence; 1992. p. 175–81.
- [2] Winter AA, Pollack AS, Odrich RB. Placement of implants in the severely atrophic posterior maxilla using localized management of the sinus floor: a preliminary study. *Int J Oral Maxillofac Implants* 2002;17:687–95.
- [3] Wallace SS, Froum SJ. Effect of maxillary sinus augmentation on the survival of endosseous dental implants. A systematic review. *Ann Periodontol* 2003;8:328–43.
- [4] Del Fabbro M, Testori T, Francetti L, Weinstein R. Systematic review of survival rates for implants placed in the grafted maxillary sinus. *J Prosthet Dent* 2005;94:266.
- [5] Peleg M, Garg AK, Mazor Z. Predictability of simultaneous implant placement in the severely atrophic posterior maxilla: a 9-year longitudinal experience study of 2132 implants placed into 731 human sinus grafts. *Int J Oral Maxillofac Implants* 2006;21:94–102.
- [6] Wahaj A, Hafeez K, Zafar MS. Role of bone graft materials for cleft lip and palate patients: a systematic review. *Saudi J Dent Res* 2015. <http://dx.doi.org/10.1016/j.sjdr.2015.02.001>. Epub Ahead of print.
- [7] Semb G. Alveolar bone grafting. *Front Oral Biol*. 2012;16:124–36.
- [8] Gross RH. The use of bone grafts and bone graft substitutes in pediatric orthopaedics: an overview. *J Pediatr Orthop* 2012;32:100–5.
- [9] Won YH, Kim SG, Oh JS, Lim SC. Clinical evaluation of demineralized bone

- allograft for sinus lifts in humans: a clinical and histologic study. *Implant Dent* 2011;20:460–4.
- [10] Irinakis T. Efficacy of injectable demineralized bone matrix as graft material during sinus elevation surgery with simultaneous implant placement in the posterior maxilla: clinical evaluation of 49 sinuses. *J Oral Maxillofac Surg* 2011;69:134–41.
- [11] Tian M, Yang Z, Kuwahara K, Nimmi ME, Wan C, Han B. Delivery of demineralized bone matrix powder using a thermogelling chitosan carrier. *Acta Biomater* 2012;8:753–62.
- [12] Groeneveld EH, van den Bergh JP, Holzmann P, ten Bruggenkate CM, Tuinzing DB, Burger EH. Mineralization processes in demineralized bone matrix grafts in human maxillary sinus floor elevations. *J Biomed Mater Res* 1999;48:393–402.
- [13] Javed F, Vohra F, Zafar S, Almas K. Significance of osteogenic surface coatings on implants to enhance osseointegration under osteoporotic-like conditions. *Implant Dent* 2014;23:679–86.
- [14] Ahn SJ, Leesungbok R, Lee SW, Heo YK, Kang KL. Differences in implant stability associated with various methods of preparation of the implant bed: an in vitro study. *J Prosthet Dent* 2012;107:366–72.
- [15] Degidi M, Daprile G, Piattelli A, Carinci F. Evaluation of factors influencing resonance frequency analysis values, at insertion surgery, of implants placed in sinus-augmented and nongrafted sites. *Clin Implant Dent Relat Res* 2007;9:144–9.
- [16] Degidi M, Daprile G, Piattelli A. RFA values of implants placed in sinus grafted and nongrafted sites after 6 and 12 months. *Clin Implant Dent Relat Res*. 2009 Sep;11(3):178–82.
- [17] Cawood JL, Howell RA. A classification of the edentulous jaws. *Int J Oral Maxillofac Surg* 1988;17:232–6.
- [18] Buser D, Ingimarsson S, Dula K, Lussi A, Hirt HP, Belser UC. Long term stability of osseointegrated implants in augmented bone: a 5-year prospective study in partially edentulous patients. *Int J Periodontics Restor Dent* 2002;22:109–17.
- [19] Albrektsson T, Zarb G, Worthington P, Eriksson AR. The long-term efficacy of currently used dental implants: a review and proposed criteria of success. *Int J Oral Maxillofac Implants* 1986;1:11–25.
- [20] Esposito M, Grusovin MG, Kwan S, Worthington HV, Coulthard P. Interventions for replacing missing teeth: bone augmentation techniques for dental implant treatment. *Cochrane Database Syst Rev* 2008;CD003607.
- [21] Lundgren AK, Lundgren D, Hämmerle CH, Nyman S, Sennerby L. Influence of decortication of the donor bone on guided bone augmentation. An experimental study in the rabbit skull bone. *Clin Oral Implants Res* 2000;11:99–106.
- [22] Slotte C, Lundgren D. Impact of cortical perforations of contiguous donor bone in a guided bone augmentation procedure: an experimental study in the rabbit skull. *Clin Implant Dent Relat Res* 2002;4:1–10.
- [23] Chen TW, Chang HS, Leung KW, Lai YL, Kao SY. Implant placement immediately after the lateral approach of the trap door window procedure to create a maxillary sinus lift without bone grafting: a 2-year retrospective evaluation of 47 implants in 33 patients. *J Oral Maxillofac Surg* 2007;65:2324.
- [24] Kutsuyama H, Jensen SS. Treatment options for sinus floor elevation. In: Chen S, Buser D, Wismeijer D, editors. *ITI treatment guide volume 5: sinus floor elevation procedures*. Chicago: Quintessence Publishing Co. Ltd; 2011. p. 33–57.
- [25] Boyne PJ, James RA. Grafting of the maxillary sinus floor with autogenous marrow and bone. *J Oral Surg* 1980;38:613–6.
- [26] Wallace SS, Froum SJ. Effect of maxillary sinus augmentation on the survival of endosseous dental implants. A systematic review. *Ann Periodontol* 2003;8:328–43.
- [27] Schwartz-Arad D, Herzberg R, Dolev E. The prevalence of surgical complications of the sinus graft procedure and their impact on implant survival. *J Periodontol* 2004;75:511–6.
- [28] Solar P, Geyerhofer U, Traxler H, Windisch A, Ulm C, Watzek G. Blood supply to the maxillary sinus relevant to sinus floor elevation procedures. *Clin Oral Implants Res* 1999;10:34–44.
- [29] Vercellotti T. Technological characteristics and clinical indications of piezoelectric bone surgery. *Minerva Stomatol* 2004;53:207–14.
- [30] Chopra P, Chopra P. Piezosurgery and its applications in periodontology and Implantology. *Int J Contemp Dent* 2011;2:16–24.
- [31] Yaman Z, Suer BT. Piezoelectric surgery in oral and maxillofacial surgery. *Ann Oral Maxillofac Surg* 2013;1:1–9.
- [32] Lozada JL, Goodacre C, Al-Ardah A, Garbacea A. Later-al and crestal bone planing antrostomy: a simplified surgical procedure to reduce the incidence of membrane perforation during maxillary sinus augmentation procedures. *J Prosthet Dent* 2011;105(3):147–53.
- [33] Jang CH, Park H, Cho YB, Song CH. Mastoid obliteration using a hyaluronic acid gel to deliver a mesenchymal stem cells-loaded demineralized bone matrix: an experimental study. *Int J Pediatr Otorhinolaryngol* 2008;72:1627–32.
- [34] Fugazzotto PA. Maxillary sinus grafting with and without simultaneous implant placement: technical considerations and case reports. *Int J Periodontics Restor Dent* 1994;14:544–51.
- [35] Tarnow DP, Wallace SS, Froum SJ, et al. Histologic and clinical comparison of bilateral sinus floor elevations with and without barrier membrane placement in 12 patients: Part 3 of an ongoing prospective study. *Int J Periodontics Restor Dent* 2000;20:117–25.
- [36] Herzberg R, Dolev E, Schwartz-Arad D. Implant marginal bone loss in maxillary sinus grafts. *Int J Oral Maxillofac Implants* 2006;21:103–10.
- [37] Sbordone L, Levin L, Guidetti F, Sbordone C, Glikman A, Schwartz-Arad D.

- Apical and marginal bone alterations around implants in maxillary sinus augmentation grafted with autogenous bone or bovine bone material and simultaneous or delayed dental implant positioning. *Clin Oral Implants Res* 2011;22:485–91.
- [38] Le Gall MG. Localized sinus elevation and osteocompression with single-stage tapered dental implants: technical note. *Int J Oral Maxillofac Implants* 2004;19:431–7.
- [39] Pjetursson B, Tan WC, Zwahlen M, Lang NP. A systemic review of the success of sinus floor elevation and survival of implants inserted in combination with sinus floor elevation. Part I: lateral approach. *J Clin Periodontol* 2008;35: 216–40.
- [40] O'Sullivan D, Sennerby L, Meredith N. Measurements comparing the initial stability of five designs of dental implants: a human cadaver study. *Clin Implant Dent Relat Res* 2000;2:85–92.
- [41] O'Sullivan D, Sennerby L, Meredith N. Influence of implant taper on the primary and secondary stability of osseointegrated titanium implants. *Clin Oral Implants Res* 2004;15:474–80.
- [42] Berglundh T, Abrahamsson I, Lang NP, Lindhe J. De novo alveolar bone formation adjacent to endosseous implants. a model study in the dog. *Clin Oral Implants Res*. 2003 Jun;14(3):251–62 [PubMed].
- [43] Lindhe j, Berglundh T, Niklaus P. *Clinical periodontology and implant dentistry*. fifth ed. Blackwell; 2008. p. 99–107.